

Six years' Experience of Fetal Echocardiography in Mothers with Gestational Diabetes Mellitus at Army Cardiac Center Lahore

Mehboob Sultan, Muhammad Waleed Baber, Saima Rafique*, Aziz Ahmed**

Department of Paediatric Cardiology, Armed Forces Institute of Cardiology, Rawalpindi/National Institute of Heart Diseases/National University of Medical Sciences (NUMS) Pakistan, *Department of Paediatric Cardiology, Army Cardiac Centre Lahore/National University of Medical Sciences (NUMS) Pakistan,

**Department of Paediatric Cardiology, Cardiac Hospital, Muzaffarabad Pakistan

ABSTRACT

Objective: To evaluate the diagnostic performance of fetal echocardiography for the prenatal detection of congenital heart disease (CHD) in pregnancies complicated by gestational diabetes mellitus (GDM).

Study Design: Cross sectional study.

Place and Duration of Study: Army Cardiac Center Lahore, Pakistan from July 2019 to July 2025.

Methodology: Out of total 2045, thirteen hundred and thirteen pregnant women diagnosed with GDM who underwent fetal echocardiography and had available postnatal echocardiographic confirmation were included. Pre-gestational diabetes, inadequate imaging, absence of postnatal echocardiography, major extracardiac anomalies, chromosomal abnormalities, and incomplete data were excluded. Fetal echocardiography was performed by pediatric cardiologists using standardized protocols. Postnatal echocardiography served as the gold standard. Diagnostic performance parameters; sensitivity, specificity, positive predictive value (PPV), negative predictive value (NPV), and overall accuracy were calculated.

Results: A total of 1,313 pregnancies were analysed. Postnatal confirmed CHD was present in 58 cases (4.4%). Fetal echocardiography correctly identified 52 cases (true positives) and missed 6 cases (false negatives), with no false positives. Sensitivity was 89.7%, specificity 100%, Positive predictive value 100%, Negative predictive value 99.5%, and overall diagnostic accuracy 99.5%.

Conclusion: Fetal echocardiography demonstrates high diagnostic accuracy for congenital heart disease screening in pregnancies complicated by gestational diabetes mellitus, when validated against postnatal echocardiography, and provides contemporary region-specific evidence from a resource-limited setting.

Keywords: Congenital Heart Disease, Fetal Echocardiography, Gestational Diabetes Mellitus, Prenatal Diagnosis.

How to Cite This Article: Sultan M, Baber MW, Rafique S, Ahmed A. Six years' Experience of Fetal Echocardiography in Mothers with Gestational Diabetes Mellitus at Army Cardiac Center Lahore. *Pak Armed Forces Med J* 2026; 76(Suppl-4): S713-S718.

DOI: <https://doi.org/10.51253/pafmj.v76iSUPPL-4.14297>

This is an Open Access article distributed under the terms of the Creative Commons Attribution License (<https://creativecommons.org/licenses/by-nc/4.0/>), which permits unrestricted use, distribution, and reproduction in any medium, provided the original work is properly cited.

INTRODUCTION

Gestational diabetes mellitus (GDM) is one of the common medical conditions that have a broad range of negative results for both the mother and the fetus. Recent reviews show that globally GDM affects roughly 15% of pregnancies, while even higher rates are reported in South Asia, including Pakistan.^{1,2} In a cross-sectional Pakistani cohort, congenital cardiac abnormalities were identified in approximately 38.7% of infants born to diabetic mothers upon echocardiographic evaluation.³

A recent meta-analysis involving over 46 million mother-child pairs demonstrated that gestational diabetes mellitus is associated with a significantly higher risk of congenital heart disease in offspring, with a pooled odds ratio of 1.32 ($p < 0.001$).² Another study by Papazoglou et al found that GDM increases

the risk of CHD in infant by 1.5 folds.⁴

Infants born to diabetic mothers are at a much higher than average risk for congenital heart disease (CHD). Population-based studies show that congenital heart disease is 2 to 5 times more common in offspring of diabetic pregnancies. These pregnancies contribute to both the growth of the heart muscle and the development of the heart structurally.⁵ Fetal hyperinsulinemia, a disturbance of the myocardial metabolism, and increased myocardial cellular growth and poor maturation of the myocardial are some of the processes that are thought to be most important in the development of this condition.⁶

Fetal echocardiography is the preferred imaging technique for the evaluation of the developing heart's anatomy and physiology. Targeted fetal echocardiography has been outlined in international recommendations for pregnancies affected by diabetes, and is recommended to take place between 18 and 22 weeks of gestational age.⁷ Major CHDs have

Correspondence: Dr Mehboob Sultan, Department of Paediatric Cardiology, Armed Forces Institute of Cardiology, Rawalpindi Pakistan

been detected with sensitivities between 80 and 90% depending on the expertise of operator, gestational age, and quality of ultrasound.⁸

In Pakistan, the burden of gestational diabetes mellitus (GDM) is rising rapidly, yet data on its fetal cardiac impact remain limited. With growing experience with fetal echocardiography in pregnancies complicated by GDM has highlighted a significant frequency of functional and structural cardiac changes, even in cases with apparently good glycemic control. Many of these abnormalities are clinically silent on routine obstetric ultrasound and become evident only on targeted fetal echocardiography. Conducting this study is therefore essential to define the true spectrum and prevalence of fetal cardiac involvement in GDM within the Pakistani population, identify high-risk subsets, and generate local evidence to guide screening protocols. Such data can inform timely prenatal counseling, optimize perinatal management, and potentially reduce neonatal cardiac morbidity through early detection and follow-up. The present study was therefore designed to evaluate the diagnostic accuracy of fetal echocardiography for screening CHD in pregnancies complicated by GDM, using postnatal echocardiography as the reference standard.

METHODOLOGY

This was a cross sectional study conducted at the Army Cardiac Center, Lahore between the time periods of July 2019 - July 2025 using non probability consecutive sampling technique. The study was approved by the institutional ethical review board (Itr#18/Estb/ACH).

Sample size of 161 was determined using WHO sample size calculator with confidence level of 95%, margin of error 5% and using 11.82 % prevalence of CHD among infants with mothers of Gestational diabetes.⁹ However total of 1313 patient's data was included in the study.

Inclusion Criteria: The study included pregnant women of any maternal age diagnosed with GDM who underwent fetal echocardiography at the study center. Only those with availability of postnatal echocardiography, and complete clinical data were considered. Both singleton and twin pregnancies with at least one viable fetus were eligible.

Exclusion Criteria: Exclusion criteria included pre-gestational diabetes, absence of fetal or postnatal echocardiography, or poor-quality fetal

echocardiographic images. Pregnancies with major extracardiac anomalies, chromosomal abnormalities, intrauterine fetal demise before assessment, or incomplete clinical/echocardiographic data were also excluded.

During the study period, 2,045 pregnancies complicated by diabetes were included. Fetal echocardiography was planned from 18 weeks gestation onwards. 732 pregnancies were excluded due to one or more of the following reasons: Pre natal fetal echocardiography was not performed, or severely suboptimal imaging, echocardiographic data and clinical data were absent, postnatal echocardiography was not performed, and clinical data was incomplete. A total of 1,313 pregnancies were included in the final analysis. These cases made up the study population for analysis of findings from fetal echocardiograms and the postnatal diagnostic confirmation.

Using high resolution ultrasound systems, pediatric cardiologists performed fetal echocardiography. Examinations were done from the second trimester and were done in accordance with protocols where four-chamber views, views of the outflow tracts, and assessments of the great vessels were included. Overall imaging quality was categorized as acceptable, difficult, or suboptimal, and interventricular septal thickness was measured in diastole. Maternal variables included age, pregnancy type, and controlled glycaemia status from the referring obstetric team. Gestational age, fetal heart rate, and findings from the prenatal and postnatal echocardiogram were variables from the fetal segment. The postnatal echo served as the gold standard for confirmation of CHD.

Statistical analysis was carried out using SPSS (Statistical Package for Social Science) software version 23. Continuous variables (maternal age, gestational age at fetal echocardiography, fetal heart rate, and interventricular septal thickness [IVSd]) were assessed for normality using the Shapiro-Wilk test and were found to be non-normally distributed; these were presented as median with interquartile ranges (IQR). Categorical variables, including pregnancy type, glycemic control, and fetal echocardiography findings, confirmed congenital heart disease (CHD), and imaging quality, were summarized as frequencies and percentages. Diagnostic performance of fetal echocardiography was evaluated by cross-tabulating prenatal findings against postnatal confirmation to calculate sensitivity, specificity, positive predictive

value, negative predictive value, and overall diagnostic accuracy.

During the study period 2045 pregnancies complicated by diabetes were assessed, out of which 732 pregnancies were excluded due to not fitting in inclusion criteria. The final study population comprised of 1313 pregnancies.

The participant’s selection process is illustrated in Figure-1.

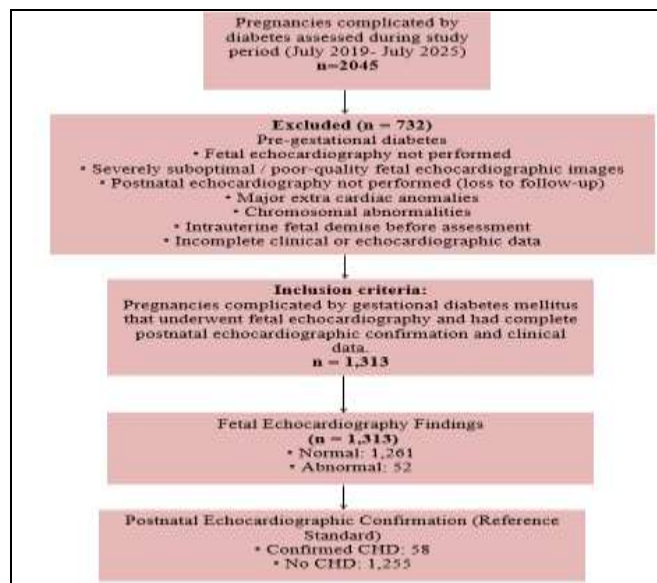


Figure-1: Flow Diagram of Participant Selection and Diagnostic Classification for Evaluation of Fetal Echocardiography in Pregnancies Complicated by Gestational Diabetes Mellitus

RESULTS

A total of 1,313 cases were examined. The demographics of maternal and fetal characteristics is in Table-I. The values for maternal age, gestational age at fetal echocardiography, fetal heart rate, and the diastolic measurement of the interventricular septum (IVSd) are shown in Table-1. Most pregnancies were singletons, and most had good glycemic control. Out of all examined fetuses, only a small proportion of fetuses demonstrated abnormal findings on fetal echocardiography; postnatal echocardiography confirmed congenital heart disease in 58 cases, including 6 cases that were not detected prenatally (Figure-2).

Among fetuses with confirmed congenital heart disease, most cases occurred in pregnancies with adequately controlled diabetes, while a small proportion were observed in poorly controlled

diabetes. The proportion of CHD was higher in pregnancies with poor glycemic control compared with those having adequate control. All confirmed CHD cases occurred in singleton pregnancies, whereas no CHD was identified among twin gestations. The cross-tabulation of CHD with glycemic control and pregnancy type is presented in Table-II.

Table-II: Association of CHD with Glycemic Control and Pregnancy Type (n=1313)

Variable		Total (n)	CHD	
			Yes	No
			Frequency (%)	
Glycemic control	Adequate	1280	56(4.4%)	1,224(95.6%)
	Poor	33	2(6.1%)	31(93.9%)
Pregnancy type	Singleton	1275	58 (4.6%)	1,217(95.4%)
	Twin	38	0(0.0%)	38 (100%)




Figure-2: Distribution of Postnatally Confirmed CHD Subtypes Among Infants Born to Mothers with GDM (n = 52)

Fetal echocardiography correctly identified 52 of 58 postnatally confirmed CHD cases, representing the true positives. There were 6 cases with CHD that were classified as normal on fetal echocardiography, representing false negatives. All 1,255 fetuses without CHD were correctly identified as normal on fetal echocardiography, representing true negatives, with no false-positive cases. Based on these data, the sensitivity of fetal echocardiography for detecting CHD was 89.7%, and the specificity was 100%. The positive predictive value (PPV) was 100%, and the negative predictive value (NPV) was 99.5%. The overall accuracy of fetal echocardiography was 99.5%. The cross-classification of prenatal echocardiographic findings against postnatal diagnosis is presented in Table-III.

DISCUSSION

The overall prevalence of postnatal confirmed congenital heart disease (CHD) in this large cohort of

Fetal Echocardiography in Gestational Diabetes

1,313 pregnancies assessed through fetal echocardiography was 4.4%. Fetal echocardiography showed encouraging levels of performance: sensitivity was 89.7%, specificity 100 %, and overall accuracy 99.5%. The test had no false positives and a negligible false negative rate, demonstrating its effectiveness in a population consisting mostly of single gestations and controlled glycemc population.

Table-III: Prenatal Fetal Echocardiography Versus Postnatal CHD Diagnosis (n=1313)

		CHD		Total
		Yes	No	
Fetal Echocardiography	Abnormal	52(89.7%)	0(0%)	52
	Normal	6 (10.3%)	1,255(100%)	1,261
Total		58	1,255	1,313
Sensitivity	Specificity	PPV	NPV	Diagnostic accuracy
89.7%	100%	100%	99.5%	99.5%

The current data advances the literature on the reliability of detailed fetal cardiac imaging done in specialized units. Kasar *et al.*, reported diagnostic accuracy for comprehensive fetal echocardiography between 86.4–94.8%, with notable concordance for major lesions.¹⁰ This reinforces the idea that with the use of standardized protocols, a population's specificity can be maximized, even in under-resourced settings. This is consistent with the initial experience reported from Jordan University Hospital, whereby the CHD detection yielded a sensitivity of 91.7 % and a specificity of 95.4 % demonstrating that high diagnostic returns can be the case in varying settings.¹¹

Present observed absence of false positives and minimal false negatives aligns with the general trend in a study by Zhang *et al.*, that detailed fetal echocardiography performs best for clinically significant cardiac anomalies. Although the pooled sensitivities for basic and extended fetal echocardiographic protocols vary widely across systematic analyses- ranging from approximately 60-85% depending on gestational age and risk group- studies also highlight that experienced operators and use of multiple cardiac views markedly improve detection rates, particularly in high-risk pregnancies such as those in your cohort.¹²

A study by Akalın *et al.*, in 2025 standardized first-trimester fetal echocardiography study (11⁺-14⁺ weeks) reported a sensitivity of 54.5% and specificity of 100% for overall CHDs, with 100% sensitivity and specificity for severe CHDs, underscoring that detailed early screening can accurately identify critical lesions

even when minor anomalies are more challenging to detect.¹³

The occurrence of six false negatives within present findings resonates with the new literature that highlights the difficulties of pinpointing the prenatal diagnosis of subtle or late manifesting lesions. A systematic review by Rittey *et al.*, of early fetal echocardiography (10–15 weeks) illustrated that while early identification of significant congenital heart defects (CHD) is possible with a high level of accuracy; minor anomalies along with functional alterations are often overlooked, requiring additional or later imaging to reach complete assessment.¹⁴

Another significant dimension of the present study is the link of CHD to the control of maternal blood sugar. Although the majority of confirmed CHD cases were during gestation with suitable blood sugar control, the CHD case fraction was higher in the diabetic cases with poor control. Evidence is emerging for the analysis of case control studies that illustrates the risk for structural and functional cardiac defects is increased with well-controlled maternal diabetes compared to non-diabetic pregnancies. There is a growing body of literature focused on the epidemiology of heart defects such as Samir *et al.*, has documented a significant and consistent increase in the prevalence of aberrant CHD and hypertrophy that reinforces the biological plausibility for maternal hyperglycemia to exert effects on fetal cardiac development regardless of glycemc control.¹⁵

Additionally, Ajaz *et al.*, study concentrating on fetal echocardiography evaluation in GDM have shown structural changes such as thicker interventricular septum and changes in the right ventricle, suggesting that there is even functional and morphological changes in well controlled pregnancies.¹⁶ Along with the systematic evidence of changed fetal cardiac function due to maternal diabetes as shown by Depla *et al.*, study, these findings warrant the surveillance of cardiac function in diabetic pregnancies, like in present cohort.¹⁷ Youssef *et al.*,¹⁸ report decreased functional and structural abnormalities of the heart in diabetic pregnancies to the detection of fetal echocardiography noting the presence of more diastolic and hypertrophic abnormalities than in uncomplicated pregnancies. The cost-effectiveness analysis of universal fetal echocardiography in diabetic women by Savitsky *et al.*, in 2024 also highlights that higher probabilities of CHD at elevated glycemc burdens strengthen the case

for targeted screening in high-risk subgroups, adding health economic rationale to your clinical emphasis on echocardiographic evaluation.¹⁹

Collectively, the comparison with recent literature indicates that present findings are robust and in line with the current understanding of fetal echocardiography's diagnostic utility and the impact of maternal metabolic milieu on fetal cardiac outcomes. Results confirm that when fetal echocardiography is performed with detailed imaging protocols in an experienced practice, it achieves excellent diagnostic accuracy, and that maternal diabetes—particularly when poorly controlled—remains a relevant risk factor for CHD. These observations reinforce recommendations for systematic cardiac imaging in pregnancies at risk and highlight areas for future research, particularly in refining early diagnostic sensitivity and investigating functional prenatal metrics in diabetic pregnancies.

LIMITATIONS OF STUDY

This study's limitations include the retrospective and single-center design, which can and limit the extent to which the findings can be generalized to situations occurring beyond tertiary and more specialized environments. The lack of long-term postnatal follow-up and the varying gestational ages of the fetal echocardiograms may have resulted in the overlooking of some subtle and/or late-appearing cardiac lesions. There is a need for future prospective multicenter studies that include more stringent standardization for the timing of fetal echocardiography and longer postnatal follow-up to improve the identification of subtle and progressing cardiac lesions.

CONCLUSION

This study confirms that fetal echocardiography is a highly accurate and dependable screening modality for the prenatal detection of CHD in pregnancies complicated by gestational diabetes mellitus when performed in a tertiary cardiac care setting. The excellent sensitivity, specificity, and overall diagnostic accuracy observed emphasize the effectiveness of standardized imaging protocols and experienced operators. These findings support the routine use of targeted fetal echocardiography in GDM pregnancies to enable early diagnosis, appropriate perinatal planning, and improved neonatal outcomes.

ACKNOWLEDGEMENT

We want to extend our gratitude for Echo department of ACC Lahore for their support and contribution in completion of the research paper.

Conflict of Interest: None.

Funding Source: None.

Authors' Contribution

Following authors have made substantial contributions to the manuscript as under:

MS & MWB: Data acquisition, data analysis, critical review, approval of the final version to be published.

SR & AA: Study design, data interpretation, drafting the manuscript, critical review, approval of the final version to be published.

Authors agree to be accountable for all aspects of the work in ensuring that questions related to the accuracy or integrity of any part of the work are appropriately investigated and resolved.

REFERENCES

1. Adnan M, Aasim M. Prevalence of gestational diabetes mellitus in Pakistan: a systematic review and meta-analysis. *BMC Pregnancy Childbirth* 2024; 24(1): 108. <http://dx.doi.org/10.1186/s12884-024-06290-9>
2. Mantri N, Goel AD, Patel M, Baskaran P, Dutta G, Gupta MK, et al. National and regional prevalence of gestational diabetes mellitus in India: a systematic review and Meta-analysis. *BMC Public Health* 2024; 24(1): 527. <http://dx.doi.org/10.1186/s12889-024-18024-9>
3. Iqbal H, Rehman SU, Abdurrazzaq, Khan AA, Ali M, Haq FU. Frequency of congenital cardiac conditions in children born to diabetic moms. *Pakistan Journal of Medical and Health Sciences*. 2023; 17(6): 378–80. <https://doi.org/10.53350/pjmhs2023176378>
4. Papazoglou AS, Moysidis DV, Panagopoulos P, Kaklamanos EG, Tsagkaris C, Vouloagkas I, et al. Maternal diabetes mellitus and its impact on the risk of delivering a child with congenital heart disease: a systematic review and meta-analysis. *J Matern Fetal Neonatal Med*. 2022; 35(25): 7685–94. <http://dx.doi.org/10.1080/14767058.2021.1960968>
5. Liu Y, Yue L, Chang L. Maternal gestational diabetes mellitus and congenital heart disease in offspring: A meta-analysis. *Horm Metab Res* 2024; 56(08): 574–584. <http://dx.doi.org/10.1055/a-2238-1710>
6. Massalha M, Iskander R, Hassan H, Spiegel E, Erez O, Nachum Z. Gestational diabetes mellitus - more than the eye can see - a warning sign for future maternal health with transgenerational impact. *Front Clin Diabetes Healthc*. 2025; 6: 1527076. <http://dx.doi.org/10.3389/fcdhc.2025.1527076>
7. Geiger MK, McBrien A, Hornberger LK, Moon-Grady AJ, Madan N, Carvalho JS, et al. Performance of early fetal echocardiography: An expert statement from the fetal heart society. *J Am Soc Echocardiogr* 2025; <http://dx.doi.org/10.1016/j.echo.2025.09.020>
8. Chu C, Yan Y, Ren Y, Li X, Gui Y. Prenatal diagnosis of congenital heart diseases by fetal echocardiography in second trimester: a Chinese multicenter study. *Acta Obstet Gynecol Scand* 2017; 96(4): 454–463. <http://dx.doi.org/10.1111/aogs.13085>
9. Alyousif SMM, Aldokhel FT, Alkhanbashi OK, Alqahtani MHA, Aladawi AMM, Ashmawi AA, et al. The incidence of congenital heart defects in offspring among women with diabetes in Saudi Arabia. *Cureus* 2021; <http://dx.doi.org/10.7759/cureus.14225>
10. Kasar T, Yurdakul Ertürk E. Fetal echocardiography findings and postnatal outcomes: Are there significant changes? *Kosuyolu Heart J* 2025; 28(3): 113–118. <http://dx.doi.org/10.51645/khj.2025.540>

Fetal Echocardiography in Gestational Diabetes

11. Tutunji L, Thekrallah F, Basha A, Awaysheh B, Amer S, Khatib L, et al. Prenatal detection of fetal heart disease at Jordan University Hospital: early experience in a developing country. *Cardiol Young*. 2019; 29(8): 1072–1077.
<http://dx.doi.org/10.1017/s1047951119001550>
 12. Zhang Y-F, Zeng X-L, Zhao E-F, Lu H-W. Diagnostic value of fetal echocardiography for congenital heart disease: A systematic review and meta-analysis. *Medicine (Baltimore)* 2015; 94(42): e1759.
<http://dx.doi.org/10.1097/md.0000000000001759>
 13. Akalın M, Akalın EE, Kara M, Büyükbayrak EE. Diagnostic performance of standardized first trimester fetal echocardiography for the detection of congenital heart defects. *J Clin Ultrasound* 2025; 53(9): 2081–2087.
<http://dx.doi.org/10.1002/jcu.70016>
 14. Rittey L, Davidson H, Hornberger LK, Eckersley L, Boehme C, McBrien A et al. Fetal echocardiography from 10 to 15 weeks of gestation—reliability, genetic associations, and outcomes. *J Am Soc Echocardiogr* 2024; 37(12): 1123–1132.e2.
<http://dx.doi.org/10.1016/j.echo.2024.08.012>
 15. Samir A, Nassar C, Idriss GM, Abou-Elyazid H, Alzahrani SA. Echocardiographic findings in infants of diabetic mothers. *Cureus* 2025; 17(9): e92493.
<http://dx.doi.org/10.7759/cureus.92493>
 16. Ajaz S, Kakroo SA, Amin H, Akram I, Rashid A. Fetal echocardiography in Gestational diabetes mellitus. *Cureus* 2025; 17(7): e89050. <http://dx.doi.org/10.7759/cureus.89050>
 17. Depla AL, De Wit L, Steenhuis TJ, Slieker MG, Voormolen DN, Scheffer PG, et al. Effect of maternal diabetes on fetal heart function on echocardiography: systematic review and meta-analysis. *Ultrasound Obstet Gynecol* 2021; 57(4): 539–550.
<http://dx.doi.org/10.1002/uog.22163>
 18. Youssef L, Miranda J, Paules C, Garcia-Otero L, Vellvé K, Kalapotharakos G, et al. Fetal cardiac remodeling and dysfunction is associated with both preeclampsia and fetal growth restriction. *Am J Obstet Gynecol* 2020; 222(1): 79.e1-79.e9. <http://dx.doi.org/10.1016/j.ajog.2019.07.025>
 19. Savitsky LM, Hamilton C, Sterrett M, Olerich K, Ma K, Albright CM. Universal fetal echocardiography for pregestational diabetes mellitus: A cost-effectiveness analysis: A cost-effectiveness analysis. *Obstet Gynecol* 2024; 144(5): 715–724.
<http://dx.doi.org/10.1097/AOG.0000000000005538>
-