

## ABDOMINAL AORTIC ANEURYSM RUPTURE MASQUERADING AS INTESTINAL OBSTRUCTION – A RARE PRESENTATION

Muhammad Jamil, Rashid Usman

Combined Military Hospital Lahore / National University of Medical Sciences (NUMS) Pakistan

### ABSTRACT

We describe a case of a 70 year old man who presented with large bowel obstruction but the physical examination deterred initial diagnosis and raised suspicion of ruptured abdominal aortic aneurysm (AAA). Subsequent investigations confirmed ruptured AAA. An immediate open surgical repair was performed and patient made a successful recovery. Ruptured AAA masquerade numerous diagnoses including large bowel obstruction; clinicians should anticipate and treat this challenging entity timely.

**Background:** Among vascular diseases, AAA approximately affects 2% of the western population<sup>1</sup>. AAA is characterized by a dilatation of the localized segment of aorta more than 1.5 times than its normal calibre. Rupture of AAA is the most life threatening surgical emergency with an overall mortality ranging from 32% to 90%<sup>2</sup>. At present, there is significant scarcity of literature regarding aortic disease in Pakistan. We report a first ever successful surgical repair of a ruptured AAA with a confounding clinical presentation of large bowel obstruction in Pakistan.

**Keywords:** Aorta, Aneurysm, Abdominal, Rupture, Intestinal obstruction.

This is an Open Access article distributed under the terms of the Creative Commons Attribution License (<http://creativecommons.org/licenses/by/4.0>), which permits unrestricted use, distribution, and reproduction in any medium, provided the original work is properly cited.

### INTRODUCTION

Among vascular diseases, abdominal aortic aneurysm (AAA) affects 2% cases of western population<sup>1</sup> approximately. AAA is characterized by a dilatation of the localized segment of aorta more than 1.5 times its normal calibre. Rupture of AAA is the most life threatening surgical emergency with an overall mortality ranging from 32% to 90%<sup>2</sup>. At present, there is significant scarcity of literature regarding aortic disease in Pakistan. We report a first ever successful surgical repair of a ruptured AAA with a confounding clinical presentation of large bowel obstruction in Pakistan.

### CASE REPORT

A 60 year male (Body Mass Index of 22) presented to emergency department with 5 days history of abdominal distension, pain and absolute constipation. He did not have any episodes of vomiting, fever, altered bowel habits, tenesmus and bleeding per rectum. Moreover, he

did not observe any recent weight loss. He did not have any preceding medical co morbidities and was on no regular medication.

On examination, his vital signs were within normal limits and cardiovascular and respiratory examinations were unremarkable. His abdominal examination revealed distension with ecchymosis

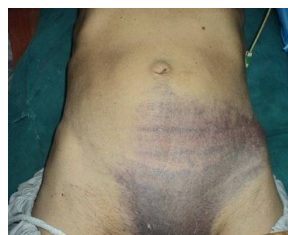

Figure-1: Ecchymosis of the left lower abdomen and groin in a patient with ruptured AAA.

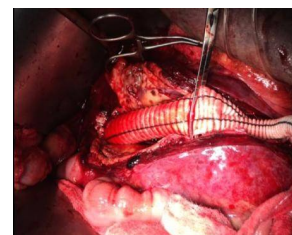


Figure-2: Placement of dacron graft after opening the AAA.

in the left lower quadrant (fig-1). He also had a large painless, pulsatile and expansile mass extending two finger breaths above the umbilicus. His bowel sounds were absent and finger could not be passed on digital rectal examination.

In review of the dissuading history, examination and the hemodynamic stability of

**Correspondence:** Dr Muhammad Jamil, Vascular Surgeon CMH Lahore Pakistan (Email: [jamilmalik13@yahoo.com](mailto:jamilmalik13@yahoo.com))  
Received: 28 Aug 2015; revised received: 01 Sep 2015; accepted: 09 Mar 2016

the patient, an ultrasound and non-enhanced computerized tomography (CT) were performed. The results demonstrated a large retroperitoneal infra renal rupture of AAA extending into the common iliac arteries measuring 11.1 cm (transverse) by 9.5 cm (antero-posterior).

Emergency open surgical repair was planned. An aortoiliac bypass was performed using Dacron graft (fig-2) and subsequently a massive clot weighing 2 kilogram was dexterously removed. He made prompt recovery. Since discharge, he has been healthy and on regular followup for last twelve months.

### DISCUSSION

Abdominal aortic aneurysm (AAA) is predominantly affecting 5-10% of men of age 65-79 year contributing a significant burden on healthcare globally<sup>3</sup>. Rupture, is the fatal complication of AAA classically known as triad of hypotension, back pain and abdominal mass is merely observed in 25-50% of patients<sup>4</sup>.

More than 80% of the infrarenal AAA rupture in the retroperitoneal cavity and fortunately get sealed off; buying some time for the patient. The retroperitoneal hematoma with its compressive effects gives rise to a variety of ambiguous signs and symptoms which include transient lower limb paralysis, testicular pain, anterior thigh pain, urinary tract infection, groin pain, inguinoscrotal mass, swelling of leg and rarely as bowel obstruction. These signs and symptoms of more common surgical conditions often mislead the initial treating clinician hence making the early diagnosis of ruptured aortic aneurysm difficult.

Open surgical repair of ruptured AAA is an

option available in developing countries like Pakistan. Over time, endovascular aneurysm repair has become established as the treatment of choice for most suitable patients in many vascular centres across the world. However, a recent meta-analysis revealed no long-term survival benefit for patients undergoing endovascular aneurysm repair compared with open surgery<sup>5</sup>.

### CONCLUSION

Acute abdominal pain in elderly especially with preceding multiple co morbidities requires rapid diagnosis so deluding conditions like ruptured abdominal aneurysm can be timely treated. An atypical history and examination dissuade the clinician but a simple bedside ultrasound can potentially save a patient's life.

### CONFLICT OF INTEREST

This study has no conflict of interest to declare by any author.

### REFERENCES

1. Bahia S, Holt J, Jackson D, Patterson O, Hinchliffe J, Thompson M. et al. Systematic Review and Meta-analysis of Long-term survival after elective infrarenal abdominal aortic aneurysm repair 1969-2011: 5 year survival remains poor despite advances in medical care and treatment strategies. *Eur J Vasc Endovasc Surg.* 2015; 50(3): 320-30.
2. Antoniou A, Ahmed N, Georgiadis S, Torella F. Is endovascular repair of ruptured abdominal aortic aneurysms associated with improved in-hospital mortality compared with surgical repair? *Interact Cardiovasc Thorac Surg.* 2015; 20(1): 135-9.
3. Vardulaki KA, Revost TC, Walker NM, Day NE, Wilkink AV, Quack CR et al. Incidence among men of asymptomatic abdominal aortic aneurysms: estimates from 500 screendetected cases. *J Med Screen* 1999; 6(1): 50-4.
4. Fielding JW, Black J, Ashton F, Slaney G, Campbell DJ. Diagnosis and management of 528 abdominal aortic aneurysms. *BMJ* 1981; 283: 355-9.
5. Stather PW, Sidloff D, Dattani N, Choke E, Bown MJ, Sayers RD. Systematic review and meta-analysis of the early and late outcomes of open and endovascular repair of abdominal aortic aneurysm. *Br J Surg.* 2013; 100(11): 863-72.