

## Tuberculosis of Pubic Symphysis – A Case Report

Tariq Sarfraz, Fizzah Alkarim\*, Soman Nadim Iqbal\*\*, Menal Aslam\*\*, Saba Aneeqa

Department of Pathology, Foundation University Medical College, Islamabad Pakistan, \*Department of Medicine, Foundation University Medical College, Islamabad Pakistan, \*\*Department of Medicine, Fauji Foundation Hospital, Rawalpindi Pakistan,

### ABSTRACT

Tuberculosis is one of the major health issues in developing countries, including Pakistan, causing significant morbidity and mortality. As far as extra-pulmonary sites of tuberculosis are concerned, pubic symphysis is a relatively uncommon site. We are reporting a unique case of tuberculosis at this rare site. A 42-year-old female reported complaints of groin pain, fever and numbness in their legs for one day. After all the investigations, the patient was put on a quadruple Anti-Tuberculosis Therapy (ATT) according to the National Institute of Health and Care Excellence (NICE) guidelines. The patient completed the ATT course for seven months and was symptom-free. She was advised to follow up on a CT scan after three months to look for a recurrence of the infection.

**Keywords:** Contrast enhanced magnetic resonance imaging (CEMRI), Tuberculosis, Extra Pulmonary Tuberculosis, Pubic Symphysis.

*How to Cite This Article:* Sarfraz T, Alkarim F, Iqbal SN, Aslam M, Aneeqa S. Tuberculosis of Pubic Symphysis – A Case Report. *Pak Armed Forces Med J* 2023; 73(6): 1883-1884.

DOI: <https://doi.org/10.51253/pafmj.v73i6.10802>

---

This is an Open Access article distributed under the terms of the Creative Commons Attribution License (<https://creativecommons.org/licenses/by-nc/4.0/>), which permits unrestricted use, distribution, and reproduction in any medium, provided the original work is properly cited.

---

### INTRODUCTION:

Tuberculosis is a well-known public health concern that remains a global challenge, resulting in significant morbidity and mortality. According to geographical distribution, Pakistan ranks sixth position among all developing countries. In collaboration with national governments, the World Health Organization (WHO) are constantly committed to its eradication.<sup>1</sup> It is considered a heterogenous disease that can involve any part of the body, the lung being the usual site.<sup>2</sup> Extra-pulmonary Tuberculosis (EPTB) accounts for 15–20% of all tuberculosis cases and is commonly missed by clinicians at the time of presentation due to a lack of constitutional symptoms.<sup>3</sup>

Osteoarticular tuberculosis comprises 3% of all cases and the involvement of pubic bone accounts for less than 1% of all musculoskeletal system cases.<sup>4</sup> As far as female genital tuberculosis is concerned, fallopian tubes are affected mostly, resulting in infertility and peritoneal adhesions. Biopsy, Culture/Sensitivity (C/S) and Polymerase Chain Reaction (PCR) for Mycobacterium Tuberculosis remain the gold standard for the definitive diagnosis of the disease.<sup>5</sup> We are reporting a unique case of tuberculosis of pubic symphysis.

### CASE REPORT

A 42-year-old woman, a school administrator by profession, presented with the complaint of sudden onset of pain in her groin, fever and numbness in her legs for one day. The pain was continuous and aggravated while walking. There was no history of athletic exertion, trauma or surgical procedure. On examination, she was febrile with tenderness in the pelvic region. She was administered intravenous painkillers and sent back to home. After a couple of days, the patient came into the Orthopaedic Outpatient department with similar complaints, where she was prescribed the same medication with additional Alprazolam and Vitamin D supplements. The symptoms did not regress. After one week, she was referred to the gynaecology outpatient department. An ultrasound of the abdomen and pelvis was done, which was unremarkable. Considering the suspicion of a complicated urinary tract infection, she was referred to the Urologist. The urine routine examination and haematological workup were normal.

Three weeks later, another ultrasound of the abdomen and pelvis was done by the Gynaecology Department, showing some opacities in the perineum. Contrast Enhanced Magnetic Resonance Imaging (CEMRI) of the abdomen revealed a collection of pus around the pubic symphysis and retropubic space. The radiological findings are shown in the Figure.

---

**Correspondence:** Dr Tariq Sarfraz, Department of Pathology, Foundation University Medical College, Islamabad Pakistan  
Received: 31 Aug 2023; revision received: 20 Oct 2023; accepted: 25 Oct 2023

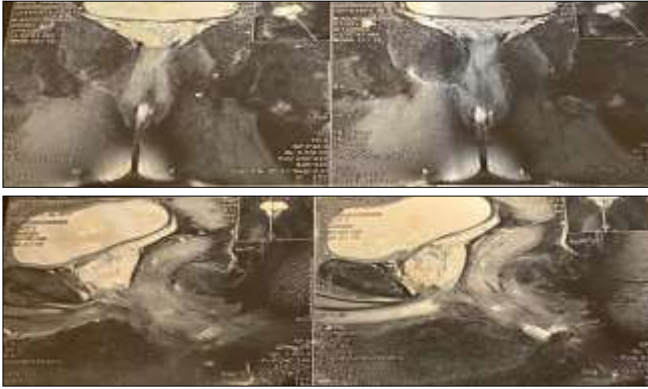


Figure: Pus formation around the Pubic Symphysis and Retropubic Space on Contrast Enhanced Magnetic Resonance Imaging (CEMRI)

A Computed Tomography (CT) guided aspiration was planned to drain the pus. The first five sessions yielded 40.0 ml of pus, which was subsequently sent for culture and sensitivity, revealing Acid-Fast Bacilli (AFB) with a slight resistance to Rifampicin. PCR for *Mycobacterium tuberculosis* was positive.

The patient was started with quadruple Anti-tuberculosis Treatment (ATT) according to the National Institute of Health and Care Excellence (NICE) guidelines, which included four tablets, including Pyrazinamide (400 mg), Ethambutol HCl (275 mg), Rifampicin (150 mg) and Isoniazid (75 mg) for seven months.

The patient completed the course of ATT for seven months and finally became symptom-free. She was advised to follow-up CT scan after three months as a surveillance.

## DISCUSSION

Pubic symphysis, being a rare site of tuberculosis with few reported cases, remains a diagnostic challenge for clinicians.<sup>6</sup> The first rare case on this particular site was reported by Jackson in 1923 in English literature.<sup>7</sup> A thorough literature research reveals that nonspecific symptomatology usually delays the diagnosis. This delay can be attributed to many mimickers presenting with a similar picture, such as osteitis pubis, juvenile osteochondritis of symphysis pubis and pyogenic osteomyelitis of symphysis pubis.<sup>7</sup> Therefore, the clinicians must keep a high index of suspicion of EPTB and take a meticulous history, including that history of trauma and order genuine investigations to make a prompt diagnosis and treatment.<sup>8</sup> Moreover, to ensure adequate diet and prevention of unnecessary weight loss, a nutritionist can also be taken on board.<sup>9</sup> A realistic and rational approach must be adopted for

timely diagnosis of this disease to prevent complications.<sup>10</sup>

To conclude, symphysis pubis is a rare site of EPTB, which is why it is kept down in the differential diagnosis. The clinician must know its mimickers and differentiate it from osteitis pubis or osteomyelitis through proper history, clinical examination and relevant investigations for its early diagnosis and prompt treatment.

## Authors Contribution

Following authors have made substantial contributions to the manuscript as under:

TS & FA & SNI & MA & SA: Conception, study design, data acquisition, drafting the manuscript, critical review, approval of the final version to be published.

Authors agree to be accountable for all aspects of the work in ensuring that questions related to the accuracy or integrity of any part of the work are appropriately investigated and resolved

## REFERENCES

1. Uddin S, Khan FU, Ahmad T, Rehman MMU, Arif M. Two Years of Retrospective Study on the Incidence of Tuberculosis in Dir Lower Valley, Khyber Pakhtunkhwa, Pakistan. *Hosp Pharm* 2018 ; 53(5): 344-349. <https://doi.org/10.1177/0018578718758603>.
2. Jeong YJ, Kang JY, Kim HW, Min J, Ko Y, Oh JY, et al. Association of Underlying Comorbidities and Sites of tuberculosis: an analysis using surveillance data. *BMC Pulm Med* 2022; 22(1): 417. <https://doi.org/10.1186/s12890-022-02224-3>.
3. Baykan AH, Sayiner HS, Aydin E, Koc M, Inan I, Erturk SM. Extrapulmonary tuberculosis: an old but resurgent problem. *Insights Imaging* 2022 ; 13(1): 39. <https://doi.org/10.1186/s13244-022-01172-0>.
4. Lal H, Jain VK, Kannan S. Tuberculosis of the pubic symphysis: four unusual cases and literature review. *Clin Orthop Relat Res* 2013 ; 471(10): 3372-3380. <https://doi.org/10.1007/s11999-013-3037-0>.
5. Sharma JB, Sharma E, Sharma S, Dharmendra S. Recent Advances in Diagnosis and Management of Female Genital Tuberculosis. *J Obstet Gynaecol India* 2021; 71(5): 476-487. <https://doi.org/10.1007/s13224-021-01523-9>.
6. Meena S, Gangary SK. Tuberculosis of symphysis pubis: A case report". *J Res Med Sci* 2015; 20(1): 100-102.
7. Singh S, Arora S, Sural S, Dhal A. Tuberculosis of the pubic symphysis masquerading as osteitis pubis: a case report. *Acta Orthop Traumatol Turc* 2012; 46(3): 223-227. <https://doi.org/10.3944/aott.2012.2696>.
8. Bali K, Kumar V, Patel S, Mootha AK. Tuberculosis of symphysis pubis in a 17 year old male: a rare case presentation and review of literature. *J Orthop Surg Res* 2010; 5: 63. <https://doi.org/10.1186/1749-799X-5-63>.
9. Kouhpayeh H. Different diets and their effect on tuberculosis prevention in HIV patients. *J Family Med Prim Care*. 2022 ; 11(4): 1369-1376. [https://doi.org/10.4103/jfmpc.jfmpc\\_1289\\_21](https://doi.org/10.4103/jfmpc.jfmpc_1289_21).
10. Arakelyan S, Karat AS, Jones ASK, Vidal N, Stagg HR, Darvell M, Horne R. Relational Dynamics of Treatment Behavior Among Individuals with Tuberculosis in High-Income Countries: A Scoping Review. *Patient Prefer Adherence* 2021; 15(1): 2137-2154. <https://doi.org/10.2147/PPA.S313633>.