

Intra-Aortic Balloon Pump Rupture leading to Cerebral Air Embolism: A Case Report

Muhammad Usama Akhtar, Imtiaz Ahmed Chaudhry, Syed Muzaffar Hasan Kirmani

Department of Adult Cardiac Surgery, Armed Forces Institute of Cardiology/National Institute of Heart Diseases/
National University of Medical Sciences (NUMS) Rawalpindi, Pakistan

ABSTRACT

Intra-Aortic Balloon Pump (IABP) rupture is relatively rare but significant complication of IABP and can lead to serious problems such as the cerebral ischemia and air embolism. The IABP insertion complication rate is reported as approximately 30%, with 2.6% experiencing major complications. Notably, balloon rupture accounts for a portion of these complications, with reported incidence ranging from <1-2%. Patients with diabetes, peripheral vascular disease, and advanced age are at higher risk. It emphasizes the need for continuous monitoring of balloon function, particularly in patients with pre-existing vascular disease. Healthcare providers should remain vigilant to monitor early signs of balloon rupture owing to the chance of development of potentially severe neurological complications. This case emphasizes the importance of early detection and management, including the precise choice of balloon size and length, and potentially the use of ultrasound to evaluate for anatomical abnormalities that could contribute to IABP rupture.

Keywords: Air embolism, Cerebral ischemia, Complication rate, Intra-aortic balloon rupture.

How to Cite This Article: Akhtar MU, Chaudhry IA, Kirmani SMH. Intra-Aortic Balloon Pump Rupture leading to Cerebral Air Embolism: A Case Report. *Pak Armed Forces Med J* 2023; 73(Suppl-3): S576-578. DOI: <https://doi.org/10.51253/pafmj.v73iSUPPL-3.10687>

This is an Open Access article distributed under the terms of the Creative Commons Attribution License (<https://creativecommons.org/licenses/by-nc/4.0/>), which permits unrestricted use, distribution, and reproduction in any medium, provided the original work is properly cited.

INTRODUCTION

Intra-Aortic Balloon Pump (IABP) has become the standard choice for patients experiencing cardiogenic shock since its first reported use in 1967.^{1,2} Common indications for IABP insertion include hemodynamic instability, cardiogenic shock, difficulty in weaning off cardiopulmonary bypass, high-risk pre-operative unstable patients, and refractory unstable angina.³ In current case, the indication for IABP support was cardiogenic shock despite high inotropic support.

CASE REPORT

This was a case of cerebral ischemia following Intra-Aortic Balloon Rupture. The patient was a 68-year old gentleman, a known case of diabetes and hypertension, who presented to the emergency department with a complaint of central chest pain for the last three hours. Based on ECG changes and raised cardiac enzymes, he was diagnosed with an acute Myocardial Infarction and initiated on thrombolytic therapy. However, this had to be abandoned as the patient developed Ventricular Tachycardia.

The patient was a non-smoker with no previous history of Ischemic Heart Disease, cerebral vascular accidents, transient ischemic attack, or carotid endarterectomy. On examination, he was alert with normal sensorium, bilaterally equally reactive pupils, 5/5 power in all limbs, no murmurs, and no carotid bruit. Echocardiogram revealed an ejection fraction of 33% with multiple regional wall motion

abnormalities and no intra-cardiac clots. Doppler ultrasound of the carotids showed no significant stenotic lesions.

Coronary angiography showed Left Main Stem (LMS) disease with critical lesions in the left anterior descending, left circumflex, and right coronary arteries. The patient was planned for surgery and prepped accordingly. He was started on injection Enoxaparin, and antiplatelet therapy was stopped.

The patient was intubated with an 8 cuffed endotracheal tube; intubation difficulty was of grade-II followed by administration of general anaesthesia.

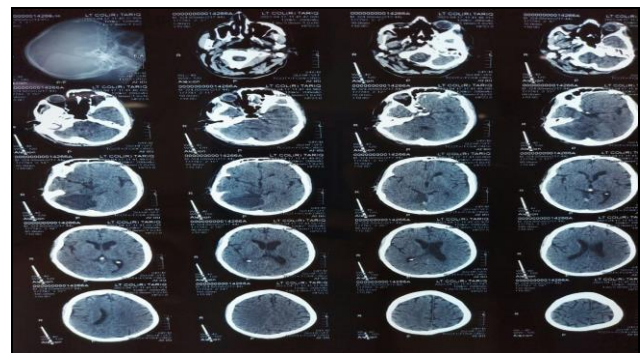


Figure-1: CT Brain; a Large fairly defined 62x51mm Hypo Dense Area in the Right Cerebellum Cerebellar Vermis and the Right Occipital Lobe

Mid-line sternotomy was performed. Full dose heparin was administered. Aortic and bicaval cannulation was done and the aorta was checked before cannulation which was supple. Bilateral carotids were palpable after cannulation. Cardiopulmonary bypass was initiated, maintaining a mean arterial pressure of more than 70mmHg. The patient re-

Correspondence: Dr Imtiaz Ahmed Chaudhry, Department of Adult Cardiac Surgery, AFIC/NIHD Rawalpindi, Pakistan

ceived intermittent, tepid, blood cardioplegia (anterograde, and retrograde) for adequate cardio protection. Three grafts were implanted, and the bypass time was 175 minutes, with a cross-clamp time of 125 minutes.

The patient was placed on high inotropic support after being weaned off the ventilator and IABP was inserted through his right femoral artery. He was then shifted to the ICU while still intubated. On the zero postoperative days, blood was seen in the helium line of the IABP, and a diagnosis of balloon rupture was made. A guide wire was passed through the old balloon and it was removed, after which a new balloon was inserted over the guide wire using the Seldinger technique. The tip of the balloon was confirmed to be in the second intercostal space on a chest X-ray. The patient remained intubated in the ICU for the next two days as he could not regain consciousness.

However, after weaning off the ventilator, the patient demonstrated significant neurological deficits. He had altered speech with weakness on the left side of his body. A plain CT scan of the brain was performed, which showed a large fairly defined 62x51mm hypo-dense area in the right cerebellum cerebellar vermis and the right occipital lobe (Figure-1). There was also loss of interface between the grey and white matter in this region, with no definitive mass effect. These findings were suggestive of a large subacute right-sided superior cerebellar artery region infarct involving the superior aspect of the right cerebellar hemisphere.

Neurological consultation was sought from the Neurology department, and he was started on neurotonic drugs. With time, the patient's weakness improved, and he was able to mobilize out of bed to a chair and walk with support. However, the patient had difficulty in balancing himself. His power improved in both the upper and lower left limbs, but he continued to have difficulty in speaking. Subsequently, a follow-up CT was performed, which revealed no further abnormality. The patient made good neurological recovery and was subsequently discharged with no neurological deficit.

DISCUSSION

The complication rate of IABP insertion has been reported to be 30%, with 2.6% of patients experiencing at least one major complication, and in-hospital mortality rate of 0.05%.³ These complications include fever, thrombocytopenia, limb ischemia, bleeding, and balloon rupture leading to entrapment⁴ and complications are more commonly seen in elderly females with diabetes and those with peripheral vascular disease.^{2,3} Patient was diabetic as

well as hypertensive, which put him at greater risk for complications.

Balloon entrapment and rupture have been reported with incidence of <2%.^{4,5} While thromboembolic phenomena can lead to distal neurovascular compromise, air emboli can cause cerebral ischemic events.⁶ Arterial air embolisms more frequently affect the brain than the spinal cord. Air bubbles lodged in a cerebral artery produce an immediate but transient blockage, followed by dissipation of the air through the capillary and venous beds. This is followed by arterial spasm and later by vascular dilatation and stasis of flow. Treatment usually involve anticonvulsant therapy and, in some cases, hyperbaric oxygen therapy.⁶ However, the majority of cases improve over time without specific treatment, as was observed in our case.

Most balloon ruptures have been reported between day 1 and 7. The presence of blood in the catheter is the most common indication of balloon rupture, observed in approximately 80% of patients. Unfortunately, alarms for gas leakage are not very sensitive, with a detection rate of only 29%. In only 8% of cases, the alarm is activated. Other indicators of IABP rupture lead to 10% decrease in efficiency and 6% unexpected balloon entrapment during removal.⁷ In our case, we observed a similar presentation with blood in the catheter line and no alarms.

Balloon related factors have been identified as the cause of balloon rupture in 31% of cases, with only 2% attributed to severe atherosclerosis as a potential cause. The mechanism involved is attributed to the friction between the balloon and the vessel wall, which can be influenced by the size and length of the balloon. However, the cause of balloon rupture remains unknown in majority (67%) of the cases.⁸

CONCLUSION

Healthcare providers should remain vigilant regarding sudden drops in balloon efficiency, and continuous monitoring of the helium line is essential to detect any sign of blood presence, as the alarm may not frequently activate. It is important to note that there is a higher occurrence of balloon rupture in patients with pre-existing vascular disease, emphasizing the need for extra caution in managing such patients. Additionally, when selecting the appropriate length and size of the vessel, particular attention should be paid, especially in cases of significant vascular disease. Performing an ultrasound examination can be beneficial in evaluating potential anatomical abnormalities that could contribute to IABP rupture.

ACKNOWLEDGEMENT

I want to share my gratitude for Comdt Exec Dir AFIC/NIHD for his support and contribution in completion of the research work.

Intra-Aortic Balloon Pump Rupture

Conflict of Interest: None.

Authors' Contributions

Following authors have made substantial contributions to the manuscript:

MUA, IAC: Study Concept, case report writing, intellectual contribution, Approval of the final version to be published.

SMHK: Critical Review, approval of the final version to be published.

Authors agree to be accountable for all aspects of the work in ensuring that questions related to the accuracy or integrity of any part of the work are appropriately investigated and resolved.

REFERENCES

1. Thiele H, Zeymer U, Thelemann N, Neumann FJ, Hausleiter J, Abdel-Wahab M, et al. Intraaortic balloon pump in cardiogenic shock complicating acute myocardial infarction: long-term 6-year outcome of the randomized IABP-SHOCK II trial. *Circulation* 2019; 139(3): 395-403. doi: 10.1161/circulationaha.118.038201
2. Kantrowitz A, Wasfie T, Freed PS, Rubenfire M, Wajszczuk W, Schork MAJTAjoc. Intraaortic balloon pumping 1967 through 1982: analysis of complications in 733 patients. 1986;57(11):976-83. doi:10.1016/0002-9149(86)90742-3
3. Kimman JR, Van Mieghem NM, Endeman H, Brugts JJ, Constantinescu AA, Manintveld OC, et al. Mechanical support in early cardiogenic shock: what is the role of intra-aortic balloon counterpulsation?. *Current heart failure reports*. 2020 Oct;17:247-60. doi:10.1007%2Fs11897-020-00480-0
4. Mizrahi I, Bose S, Leibowitz A. Management of intra-aortic balloon rupture and entrapment. *Journal of Cardiothoracic and Vascular Anesthesia* 2019; 33(7): 1983-1987. doi:10.1053/jjvca.2018.08.023
5. Ali O, Egolom U, Lindenfeld J. The Enigma of Spontaneous Intra-Aortic Balloon Pump Rupture. *J Cardiac Failure* 2017; 23(8): S127. doi:10.1016/j.cardfail.2017.07.374
6. Haykal HA, Wang A-MJCr. CT diagnosis of delayed cerebral air embolism following intraaortic balloon pump catheter insertion. 1986;10(6):307-9. doi: 10.1016/0730-862(86)90036-3
7. Nishida H, Koyanagi H, Abe T, Arai H, Hirayama H, Hirayama T, et al. Comparative Study of Five Types of IABP Balloons in Terms of Incidence of Balloon Rupture and Other Complications: A Multi-Institutional Study. *Artificial Organs*. 2008 Oct;18(10):746-51. doi: 10.1111/j.1525-1594.1994.tb03313.x
8. Lin Y, Sun T, Cheng NN, Liu JJ, He LX, Wang LH, et al. Anesthesia management of patients undergoing off-pump coronary artery bypass grafting: A retrospective study of single center. *Frontiers in Surgery*. 2023 Jan 30;9:1067750.