

## IMMUNOHISTOCHEMICAL EXPRESSION OF ALPHA METHYLACYL-COA RACEMASE (AMACR) IN CARCINOMA PROSTATE IN PAKISTANI POPULATION

Hassan Tariq, Rabia Ahmed, Iqbal Muhammad, Saeed Afzal, Shoaib Naiyar Hashmi, Syed Naeem Raza Hamdani, Arooj Shahid\*

Armed Forces Institute of Pathology (AFIP)/ National University of Medical Sciences (NUMS) Rawalpindi Pakistan, \*Combined Military Hospital/ National University of Medical Sciences (NUMS) Rawalpindi Pakistan

### ABSTRACT

**Objective:** To determine the frequency of expression of positive diagnostic marker alpha methylacyl-CoA RACEMES (AMACR) in the examination of prostate needle biopsy specimens from patients of adenocarcinoma prostate from a subset of Pakistani population.

**Study design:** Cross-sectional study.

**Place and Duration of Study:** Department of Histopathology, Armed Forces Institute of Pathology, Rawalpindi from Apr 2015 to Oct 2015.

**Material and Methods:** All specimens of adenocarcinoma prostate diagnosed at Armed forces institute of pathology on the basis of immunohistochemistry and routine histopathology irrespective of age of patient, histological type or grade of the tumor were analyzed. Mean and Standard deviation were calculated for quantitative variables like patient's age and frequencies along with percentages were calculated for qualitative variables like AMACR expression.

**Results:** Out of the total 80 cases, 68 (85%) were positive for AMACR while 12 (15%) were negative. Among the cases that were negative 9 (11.3%) showed 1 ± staining (Weak, non-circumferential) and 3 cases (3.8%) displayed 0 staining (No cytoplasmic staining).

**Conclusion:** Positive staining for AMACR can be used to support a diagnosis of cancer on prostate needle core biopsies when the focus in question is <1mm in maximum dimension. The results of AMACR expression in a subset of Pakistani population are comparable to the western studies. AMACR staining must be interpreted in the context of basic haematoxylin and eosin criteria for malignancy along with the results expansion of other supportive markers, such as a basal cell specific marker like p63 or 34βE12.

**Keywords:** Alphamethylacyl-CoA racemase (AMACR), Adenocarcinoma prostate, Immunohistochemistry.

---

This is an Open Access article distributed under the terms of the Creative Commons Attribution License (<http://creativecommons.org/licenses/by/4.0>), which permits unrestricted use, distribution, and reproduction in any medium, provided the original work is properly cited.

---

## INTRODUCTION

Prostate cancer is the second most common cancer in men worldwide, with an estimated 900,000 cases and 258,000 deaths in 2008<sup>1</sup>. It has been reported that it was the third commonest malignancy in males comprising almost 7% of all malignant neoplasm in male<sup>2</sup>.

The timely diagnosis of carcinoma prostate is of utmost importance because approximately 40-50% of patients with limited cancer had moderately advanced or advanced carcinoma on final radical prostatectomy<sup>3</sup> therefore, under diagnosis of a small focus of prostatic

adenocarcinoma might delay early treatment and cause severe adverse consequences for patients. The diagnosis of prostatic cancer is based on a combination of architectural, cytological and ancillary features. Accurate tissue diagnosis can be very challenging due to the presence of either a small focus of cancer or due to the presence of many benign mimickers of malignancy like adenosis. Although immunohistochemical stains for basal cells, such as high molecular weight cyto-keratin (HMWCK) or more recently p63 can aid in the diagnosis of focal prostate cancer, there are limitations in their use. Negative staining for basal cell markers is by itself not diagnostic of carcinoma. A positive immunohistochemical marker specific for prostate cancer would therefore be of great value in increasing the level

---

**Correspondence:** Dr Hassan Tariq, H#25 Street#6 Sector-A DHA-II Islamabad Pakistan (Email: [hassantariqamc@gmail.com](mailto:hassantariqamc@gmail.com))

Received: 05 Dec 2016; revised received: 21 Feb 2017; accepted: 09 Mar 2017

of confidence required to establish a definitive malignant diagnosis<sup>6</sup>. Alpha methylacyl-COA racemase (AMACR), also known as p504s, is a cytoplasmic enzyme shown by CDNA expression microarray to be overexpressed in most prostate adenocarcinomas and in high-grade prostatic intraepithelial neoplasia (HGPIN), but virtually undetectable or only weakly expressed in benign glands. Although AMACR has been a useful diagnostic marker for prostate adenocarcinoma in western countries, its effectiveness in Pakistani populations has not been reported. Recently it has been reported that sensitivity and specificity of AMACR for the diagnosis of prostate adenocarcinoma and benign glands in Japanese patients are lower than those previously reported in western countries<sup>7</sup>.

This study was conducted to analyze the frequency of expression of positive diagnostic marker AMACR in the examination of prostate needle biopsy specimens from patients of adenocarcinoma prostate from a subset of Pakistani population.

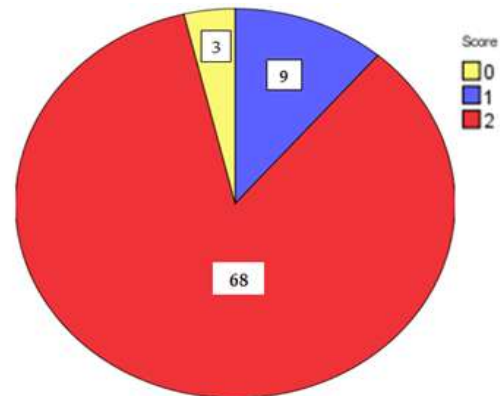
## MATERIALS AND METHODS

This cross-sectional descriptive study was carried out at Armed Forces Institute Of Pathology (AFIP), Rawalpindi from Apr 2015 to Oct 2015. A sample size of 80 was calculated using WHO sample size calculator keeping the confidence level % at 95%, anticipated population proportion at 70.66, absolute precision required at 10%. After approval by Ethical Review Committee, all specimens of adenocarcinoma prostate detected by routine histopathology and immunohistochemistry irrespective of age of patient, histological type and grade of the tumor, were included by non probability, consecutive sampling technique. Cases with inadequate biopsy were excluded from the study. Age and histopathological diagnosis was noted. All specimens were of patients of Pakistani origin. The data was analyzed by using computer software program SPSS version 19. The results of immunohistochemistry were examined microscopically and verified by the single

consultant to exclude observer bias. No cytoplasmic staining for AMACR expression was scored as 0 and interpreted as Negative, Weak, non-circumferential staining was scored as 1 and interpreted as Negative and Strong, circumferential staining was scored as 2 and interpreted as Positive fig-1. Descriptive statistics like frequency were calculated for age.

## RESULTS

A total of 80 cases were sampled from AFIP. The distribution of cases according to different age groups is summarized in table-I. The mean age of patients was  $66.16 \pm 8.44$  years (Range 55-83 years). Most of the patients were from 6th and 7th decade of life followed by 5th and 8th decade (table-I). Out of the total 80 cases, 68 cases (85%) of adenocarcinoma prostate showed positivity for AMACR while 12 cases (15%) were negative. Among the cases that were negative 9 cases (11.3%) showed  $1 \pm$  staining (Weak, non-



**Figure-1: Cytoplasmic positivity of AMACR. (a) Specific clumpy granular staining of AMACR in benign prostate gland (b) Weak diffuse nonspecific biotin labeling in a case labeled with AMACR diagnosed as being negative.**

circumferential) and 3 cases (3.8%) displayed 0 staining (No cytoplasmic staining) (table-II and fig-2). A  $p=0.269$  for age was considered statistically significant.

## DISCUSSION

Prostate cancer is one of the most common cancers worldwide and the leading cause of death by cancer in men in western countries with a matching incidence rate in subcontinent. Its

prevalence can be judged from the fact that prostate cancer alone accounted for 258,000 deaths in 2008<sup>1</sup>. Currently the risk of prostate cancer in a lifetime for men living in the United

the need to improve the specificity of diagnosis is also increasing. The need to give a timely diagnosis of carcinoma prostate is of utmost importance because it has been reported that

**Table-I: Age and intensity of AMACR staining score.**

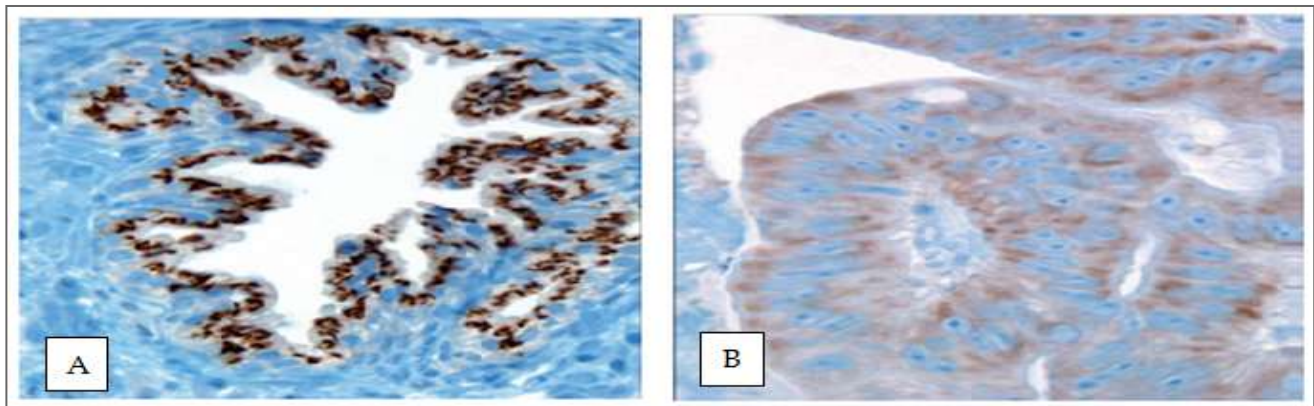
Intensity Score	Age			Total
	50-60	61-70	71-85	
0	0	2	1	3
1	2	2	5	9
2	23	28	17	68
Frequency	25	32	23	80
Percentage	31.2	40	28.8	100

**Table-II: Result and intensity of AMACR staining score.**

Result	Intensity Of AMACR Staining Score			Total
	0	1	2	
Negative Positive	3	9	0	12
	0	0	68	68
Total	3	9	68	80

States is calculated to be approximately one in six<sup>2</sup>. The incidence rate of prostate cancer in Pakistan with age adjustment is 5.3 per 100,000 person years and increasing number of cases are

approximately 40-50% of patients with limited cancer had moderately advanced or advanced carcinoma on final radical prostatectomy<sup>5</sup> Therefore there is a real threat that under



**Figure-2: Scoring of intensity of cytoplasmic staining of AMACR.**

being reported in recent years<sup>3</sup>. It has been reported that a man's lifetime risk of being diagnosed with prostate cancer is 1 in 8<sup>4</sup>.

The widespread use of serum prostate specific antigen PSA as a mass screening test for prostate cancer is resulting in an increase in the number of prostate needle biopsies and therefore

diagnosis of a small focus of prostatic adenocarcinoma might delay early treatment and cause severe adverse consequences for patients. The diagnosis of prostatic cancer is based on a combination of architectural, cytological and ancillary features but accurate tissue diagnosis can become very difficult due to the presence of

either a small focus of cancer or due to the presence of many benign mimickers of malignancy like adenosis. Immunohistochemical stains for basal cells, such as HMWCK or more recently p63 are currently used in the diagnosis of focal prostate cancer but there are limitations in their use as negative staining for basal cell markers is by itself not diagnostic of carcinoma and also due to technical reasons these stains may be falsely positive thus it is necessary to interpret negative staining in an atypical focus in light of positive staining in adjacent benign glands which is used as an internal positive control. A positive immunohistochemical marker specific for prostate cancer would therefore be of great value in increasing the level of confidence required to establish a definitive malignant diagnosis<sup>6</sup>. AMACR is a cytoplasmic enzyme that has found to be over expressed in most prostate adenocarcinoma and in HGPIN by immunohistochemical techniques. But it is mostly undetectable or only weakly expressed in benign glands. AMACR stain has been reported as a very important diagnostic marker for prostate adenocarcinoma in Western countries but its usefulness in Pakistani population has not been reported. Recently it has been reported that sensitivity and specificity of AMACR for the diagnosis of prostate adenocarcinoma and benign glands in Japanese patients are lower than those previously reported in western countries<sup>7</sup>. In Japanese population it was reported to be (70.6%) as opposed to (95%) in western population<sup>8</sup>.

Results of immunohistochemistry for AMACR showed positivity in 85% cases as compared to 70.6% carried out on Japanese which was significantly lower than 82% and, 92%, in different international studies<sup>8,9</sup>. The study conducted by Yamada et al raised doubts about the specificity of AMACR as a reliable positive marker for adenocarcinoma prostate. It also raised the question whether this marker is a race specific marker? However results in the current study in a subset of Pakistani population are

comparable with international studies. The difference in expression of AMACR in various studies might be due to the differences in sample size, methodology used and types of cases selected for study.

## CONCLUSION

Positive staining for AMACR/P504S can be used to support a diagnosis of cancer on prostate needle core biopsies when the focus in question is <1mm in maximum dimension. The results of AMACR expression in a subset of Pakistani population are comparable with the western studies. AMACR staining must be interpreted in the context of basic haematoxylin and eosin criteria for malignancy along with the results expansion of other supportive markers, such as a basal cell specific markers like 34βE12 or p63.

## CONFLICT OF INTEREST

This study has no conflict of interest to declare by any author.

## REFERENCES

1. Jemal A, Bray F, Center MM, Ferlay J, Ward E, Forman D. Global cancer statistics. *CA Cancer J Clin* 2011; 61: 69-90.
2. Siegel R, Ward E, Brawley O, Jemal A. Cancer statistics. The impact of eliminating socioeconomic and racial disparities on premature cancer deaths. *CA Cancer J Clin* 2011; 61: 212-36.
3. Mahmood S, Qasmi G, Ahmed A, Kokab F, Zahid MF, Afridi MI, Razzaq A, et al Lifestyle factors associated with the risk of prostate cancer among Pakistani men. *J Ayub Med Coll Abbottabad* 2012; 24: 111-5.
4. Ahmad Z, Azad NS, Yaqoob N, Husain A, Ahsan A, Khan AN, et al. Frequency of primary solid malignant neoplasms in both sexes, as seen in our practice. *J Ayub Med Coll Abbottabad* 2007; 19: 53-5.
5. Kumaresan K, Kakkar N, Verma A, Mandal AK, Singh SK, Joshi K. Diagnostic utility of α-methylacyl CoA racemase (P504S) & HMWCK in morphologically difficult prostate cancer. *Diagn Pathol* 2010; 5: 83.
6. Magi-Galluzzi C, Luo J, Isaacs WB, Hicks JL, de Marzo AM, Epstein JI. Alpha-methylacyl-CoA racemase: A variably sensitive immunohistochemical marker for the diagnosis of small prostate cancer foci on needle biopsy. *Am J Surg Pathol* 2003; 27: 1128-33.
7. Yamada H, Tsuzuki T, Maeda N, Yamauchi Y, Yoshida S, Ishida R, et al Alpha methylacyl-CoA racemase (AMACR) in prostate adenocarcinomas from Japanese patients: is AMACR a "race"-dependent marker? *Prostate* 2013; 73: 54-9.
8. Beach R, Gown AM, De Peralta-Venturina MN, Folpe AL, Yaziji H, et al. P504S immunohistochemical detection in 405 prostatic specimens including 376 18-gauge needle biopsies. *Am J Surg Pathol* 2002; 26: 1588-96.
9. Jiang Z, Wu CL, Woda BA, Dresser K, Xu J, Fanger GR, Yang XJ. P504S/ alpha - methylacyl-CoA racemase: a useful marker for diagnosis of small foci of prostatic carcinoma on needle biopsy. *Am J Surg Pathol* 2002; 26: 1169-74.